

# Tissue reaction to bone plates made of pure titanium: a prospective, quantitative clinical study

A. UNGERSBOECK, V. GERET, O. POHLER  
*AO/ASIF Research Institute, CH-7270 Davos, Switzerland*

M. SCHUETZ  
*AO/ASIF Documentation, CH-7270 Davos, Switzerland*

W. WUEST  
*Institute for Pathology, Cantonal Hospital Chur, CH-7000 Chur, Switzerland*

---

In 54 patients fractures of the long bones were stabilized with limited-contact dynamic compression plates (LC-DCP) made of titanium. The implant surfaces were anodized to an interference colour of gold. The surface morphology effects the tissue response to the implant and was therefore examined. At implant retrieval, about 18 months post operatively (range 11 to 27), samples of the soft tissue layer covering the plate were excised and analysed by histomorphometrical means. The aim was to study the soft tissue reactions at the implant site and further to correlate it to the clinical symptoms of the patients. At retrieval the plates were covered by a connective tissue layer of 2 mm thickness on average. In patients with local pain a comparatively significant higher number of round cells ( $p=0.001$ ) and macrophages ( $p=0.01$ ) was found. This is consistent with a chronic granulomatous inflammatory reaction. The localized tissue discoloration observed in about half of the patients was confirmed as being due to titanium, but it was not the focus of a cellular reaction and was not correlated with pain. In general the implant showed good biocompatibility with excellent or good clinical results in 96% of patients.

---

## 1. Introduction

The thickness, structure, and cellular composition of the soft tissue layer covering an implant depends on the biocompatibility of the material, and on the configuration and chemistry of the implant surface [1–7].

A successful implant material must be biocompatible; its mechanical properties during the period of implantation must be such that the implant will fulfill its function adequately. Furthermore, it should be available in sufficient quantities and at acceptable costs. The limited-contact dynamic compression plate (LC-DCP) is made of commercially pure titanium (cp Ti) [8]. Titanium has been used as an implant material for approximately 30 years. Many publications describe the excellent qualities of cp Ti as an implant material. High corrosion resistance is reported by several authors [6, 9, 10, 12]. Cp Ti implants have also proved to have excellent biocompatibility [2, 13–16]. Strongly suggesting a very low allergenic potential, contact sensitivity to Ti has been reported in only one patient who was sensitive to several other metals [17]. The allergenic potential is an important factor if an implant has to sustain its mechanical qualities over the long term. Local and systemic allergic reactions

to the implant material and its corrosion products must be prevented.

The strength and ductility of cp Ti are slightly less than those of stainless steel. However, by appropriate manufacturing, these properties can be improved to very satisfactory levels. The low-load/high-cycle fatigue characteristics of cp Ti are even better than the fatigue characteristics of implant steel [6, 12, 18].

The preparation of the surface which contacts the surrounding tissue is also important [18]. The structure and chemical properties of the outermost atomic layers of the implant and the adjacent molecular layers of the tissue characterize the interface, which partly determines the success of the implant [19]. There may be little biochemical difference between ceramic implants and cp titanium implants covered with an oxide film [18]. The thickness of a naturally formed oxide film is in the order of 5 nm. During the period of implantation the oxide layer increases to 40 nm [20]. Elements such as phosphorus, calcium, and sulphur, may be incorporated at the same time [21]. This oxide layer protects the implant from corrosion and limits the diffusion of metal ions into adjacent tissue. It is these qualities of the oxide layer that provide for good tissue acceptance and good

tissue adhesion [18]. However, the roughness of the surface is also a factor which can be expected to play a dominant role in soft tissue adhesion [3, 22–24].

This study examines the relationship between the clinical outcome, the severity of the type of fractures, the local macroscopic observations, and, most importantly, the histological soft tissue evaluation. In samples in which macroscopic discoloration of the soft tissue was seen and in the light microscope, particles as black grains were observed, and atomic absorption analysis was applied. In addition the surface roughness of the titanium plates was analysed.

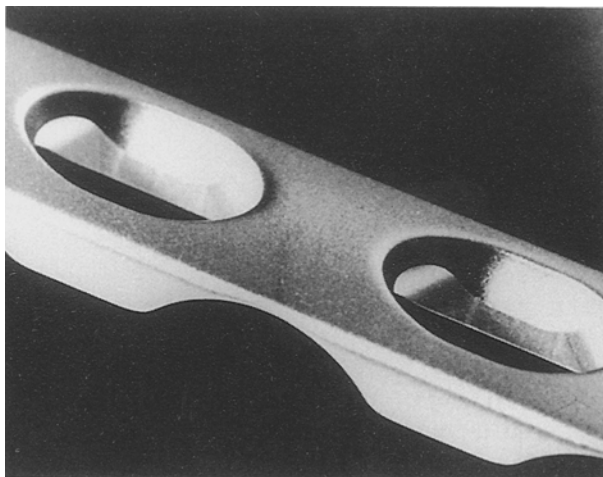
## 2. Materials

### 2.1. Implants

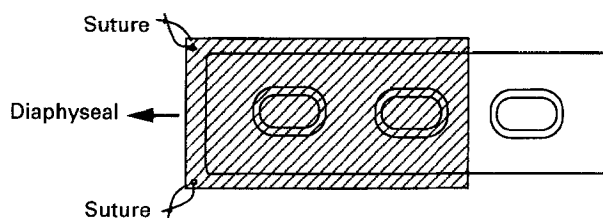
A narrow limited-contact dynamic compression plate (LC-DCP, AO/ASIF-design) was used with 4.5 mm cortical screws (Fig. 1). All implants were made from commercially pure titanium (cp Ti) corresponding to AO internal specifications [8].

The material is also covered by an international standard (ISO 5833/2, International Standard Organization). The plates had the following dimensions: thickness 4.6 mm, width 13.5 mm, hole distance 18 mm. The length was selected according to the type of fracture to allow screw fixation for about five cortices in each fragment. The surface of the plates and screws was anodized to generate a layer of titanium dioxide that shows the interference colour gold.

The surface roughness of non-implanted plates was determined using a profilometer (Taylor-Hobson) with a tip diameter of 4  $\mu\text{m}$ . Five measurements on three randomly chosen plates were carried out (measure distance 5 mm). The following parameters were measured on the implant surface [25] in accordance with ISO 4287/1, DIN 4762/1:  $S_m$ , the arithmetic mean of the groove distance,  $R_a$ , the arithmetic mean of the roughness height,  $R_a$ , the arithmetic mean of the roughness.



*Figure 1* The small (4.5 mm) limited-contact-dynamic compression plate (LC-DCP) made of commercially pure titanium (cp Ti). The special geometrical feature of the LC-DCP provides a reduced contact area with the bone in order to preserve vascularity by the introduction of undercuts between the screw holes.



*Figure 2* Mode of sample removal. Resection of the soft tissue envelope covering the plate at its diaphyseal end including at least two screw holes. After marking the tissue orientation at the two diaphyseal corners with Dexon threads, the specimens are kept in 4% formol until preparation for histomorphometric analysis.

### 2.2. Clinical material

Fifty-four patients (27 men and 27 women) with a mean age of 40 years ( $\pm 15$  years) were analysed. Clinical and radiographic case histories were available for all of them. The following clinics were involved: Basle, Chur, Davos, Fribourg, Hannover, Innsbruck, Karlsruhe, Olten, Tübingen. A defined part of the soft tissues covering the plates was used for histological analyses (Fig. 2). A light microscope with a motorized stage connected to a personal computer was used for evaluation. After entering the area of evaluation for a sample, the motorized stage moved automatically to the coordinates of randomly distributed and separate microscopic fields [26].

## 3. Methods

### 3.1. Patient characteristics

Fractures of the long bones were stabilized using the LC-DCP for internal fixation. The results of the first consecutive 54 patients in a continuing clinical study are presented. The operations were carried out by experienced surgeons in selected test clinics according to the general guidelines for internal fixation of the AO/ASIF [27]. After bone healing the implants were retrieved. The period of implantation averaged 18 months (range 11 to 27) depending on a number of factors including type of fracture, condition of bone, and rate of healing. There was a wide spectrum of indications for surgery from the various test clinics, this included patients from ski accidents (17 patients), other sports accidents (9), road accidents (14), tumour (1), and others (13). One patient who developed an osteitis was excluded.

### 3.2. Documentation

All cases were recorded at the database of the AO-Documentation Centre. Demographic data such as age, weight, sex, and pre-existent problems were collected. Information concerning the treatment such as the type of fixation, technical data, and treatment problems as well as subjective and objective assessment of the patients were documented in a routine manner using standard code sheets. The clinical data were recorded at the beginning and end of treatment. Macroscopic observations at the time of retrieval were recorded using a special code sheet. The fractures were

classified according to the AO classification for long bone fractures: simple (type A), multifragmentary simple (type B), and multifragmentary complex (type C) [28].

### 3.3. Tissue sampling

Before the implant was removed, a sample of the tissue layer covering the plate was carefully excised according to the following procedure:

- skin incision at the scar site;
- careful approach to the tissue covering the plate;
- resection of the soft tissue which covers the plate at its diaphyseal end, including two screw holes (Fig. 2);
- fixation of a Dexon thread at the diaphyseal edges of the tissue sample;
- tissue samples were pinned to polystyrene blocks by two plastic staples, to keep the tissue stretched;
- immersion in 4% formalin for tissue preservation.

### 3.4. Histological preparation

Preparation of the tissue samples corresponded to standard procedures using methylmethacrylate embedding. The specimens were sectioned perpendicular to the implant tissue interface. Six micrometer sections were cut using a Zeiss microtome and stained according to Giemsa technique.

### 3.5. Morphometric analyses

The histological evaluation was carried out at a nominal magnification of 400x using an optical microscope. For evaluation the tissue sample was divided into two zones (Fig. 6). The inner zone, a layer of dense connective tissue with cells and fibres oriented parallel to the implant. The outer zone, a layer of loose connective tissue separated from the implant by the inner zone. Statistical procedures were applied to calculate the number of microscopic fields to be evaluated in each sample [26].

The thickness of both zones was measured. The following different cell types were distinguished by their staining behaviour and morphology [29]: connective tissue cells (CTC), polymorphonuclear leukocytes (PNC), macrophages (MP), round cells (RC), mast cells (MSC). Connective tissue cells in-

cluded fibroblasts and fibrocytes, round cells included lymphocytes and plasma cells. The number of blood vessels were counted according to their inner diameter: small vessels (SV, < 20 μm), medium vessels (MV, 20–40 μm), large vessels (LV, > 40 μm). Cells circulating in blood (PNC, RC), were counted only when localized in the tissue or in the vessel wall, and were not counted when localized within the vessel. In samples with tissue discolouration, in which titanium particles were detected as black grains under the light microscope, atomic absorption analysis was carried out to confirm qualitatively the presence of titanium. A software program calculated the number of histological structures for each strip 50 μm away from the implant–tissue interface border (distance histogram). The vessels and cell types were calculated in numbers/mm<sup>2</sup>. For statistical calculations, the unpaired double sided standard t-test was used.

## 4. Results

The measurement of the surface roughness showed the following results  $S_m$  (arithmetic mean of the groove distance) =  $49.6 \pm 5.5 \mu\text{m}$  (mean  $\pm$  standard deviation),  $R_t$  (arithmetic mean of the roughness height) =  $5.7 \pm 1.4 \mu\text{m}$ ,  $R_a$  (arithmetic mean of the roughness) =  $0.4 \pm 0.1 \mu\text{m}$ .

The global clinical outcome, the subjective and objective assessments and the local findings on plate removal are summarized in Table I. The type of fracture was classified as simple in 22 cases, moderate in 24 cases, and severe in eight cases. Twenty-five patients out of a total of 54 did not report local pain. The rest of the patients mentioned different degrees and types of pain. One of the patients had local swelling. In 44 cases there was no callus visible on the radiographs, three patients showed an irritation callus (cloudy structure) and in seven patients a fixation callus (homogeneous structure) was found. In 31 cases the surgeons judged the result as excellent, while 26 patients came to the same conclusion. Twenty-five patients considered the result as good and only four patients judged the results as moderate. The surgeons judged 21 results as good, and two as moderate.

At plate removal connective tissue covering the plate was found in all cases but two, in which bony tissue was observed in addition. Localized tissue discolouration was found to a small extent in 21 patients. In two patients pronounced dark local tissue

TABLE I The global clinical outcome, the subjective and objective assessments and the local findings at the time of plate removal, with some data on the patients and the type of fracture

Sex	female 27	male 27		
Pain	no 25	slight 20	strong 3	at loading 6
Weather sensitivity	no 43	yes 11		
Local swelling	no 53	slight 1		
X-ray	no callus 44	irritation callus 3	fixation callus 7	
Judgement patient	excellent 26	good 25	moderate 3	fair 0
Judgement surgeon	excellent 31	good 21	moderat 2	fair 0
Tissue layer	soft tissue 52	bone tissue 2		
Tissue discoloration	no 31	slight 21	strong 2	
Plate bed	vascularized 41	avascular 2	combined 11	
Fracture	simple 22	moderate 24	severe 8	

impregnation was found. One of these two findings was explained by a loose screw, which led to wear at the screw hole. In 31 patients no discolouration was present. In all cases reported to us, the surgeons described intimate contact between plate and the adjacent soft tissue. The plate bed on the side of the bone was described as vascularized (bleeding) in 41 patients, as avascular (no bleeding) in two patients, and partially vascularized in 11 patients. The spaces of the LC-DCP undercuts were reported to be filled with either bony or partly soft tissues depending on the bone curvature underneath the plate.

The main aim of this study was the histomorphometric evaluation of the soft tissues covering the plates. Fig. 3 shows a survey of the histological results for all specimens based on averaged values.

Figs 4 and 5 show histograms illustrating the populations of cell types and blood vessels for all specimens as a function of distance from the plate surface. The results showed a high number of connective tissue cells in the inner zone (CTC, Fig. 5), but only few cells of

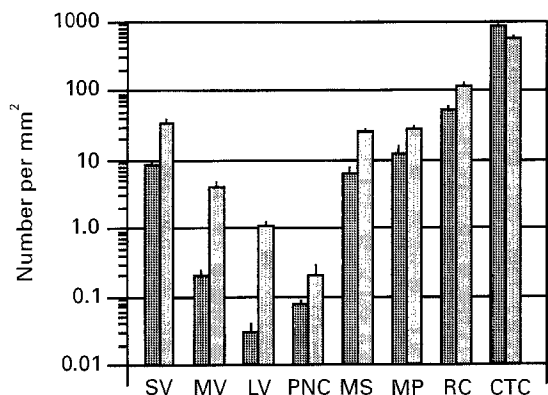


Figure 3 Display, on a logarithmic scale, of the number of cells and blood vessels found for all specimens in the inner (■) and outer (□) tissue zone adjacent to the implant. The standard error of the mean ( $n/mm^2 \pm SEM$ ) is indicated. Except for the connective tissue cells (CTC), the population of the different histological structures is higher in the outer zone (for abbreviations see Table II).

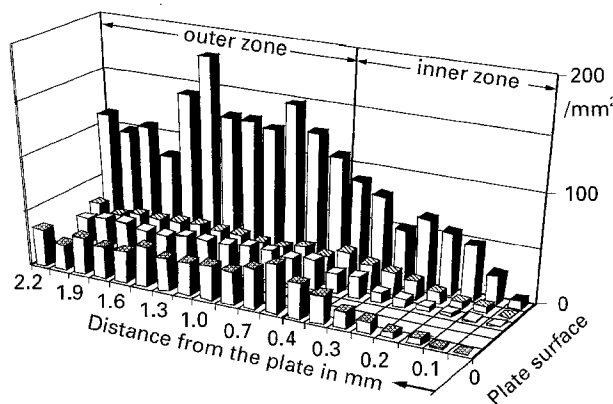


Figure 4 Distance histogram for all specimens. Number of structures per unit area counted in tissue segments of 50  $\mu m$  and 150  $\mu m$  width in the inner and outer zones of the adjacent tissue respectively. The distance of the evaluated tissue segments from the plate surface is indicated. The density of evaluated structures increases with the distance from the implant. ■ small blood vessels; □ mast cells; ▨ macrophages; ■ round cells.

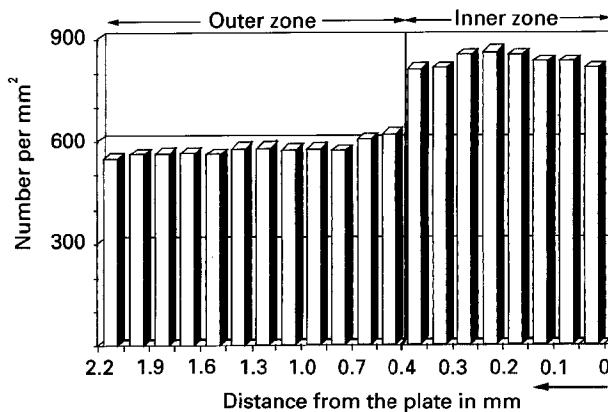


Figure 5 Distance histogram. Number of CTC (connective tissue cells) per unit area counted in tissue segments of 50  $\mu m$  and 150  $\mu m$  width in the inner and outer zones, respectively. The distance of the tissue segments from the plate surface is indicated. The number for CTCs is higher in the inner zone than the outer zone.

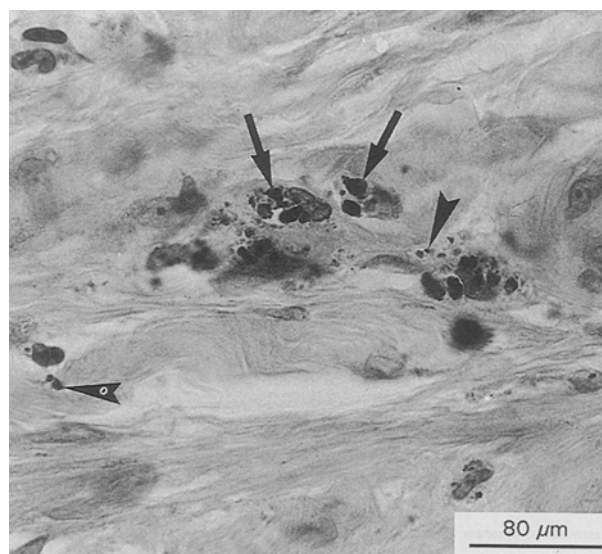


Figure 6 Part of a representative histological section of the soft tissue covering the plate (Giemsa staining, nominal magnification 100x). The implant tissue interface is indicated by arrowheads. The tissue was subdivided into the inner zone (area of dense connective tissue with cells and fibres parallel to the implant) and the outer zone (zone of loose connective tissue separated from the implant by the inner zone). The border of these two zones is indicated by arrows.

other types (Fig. 4). In the outer zone, the number of CTCs was reduced while all other cell types and the blood vessels increased in number compared to the inner zone. The thickness of the inner zone was 420  $\mu m$  ( $\pm 69 \mu m$  SD) on average and for the outer zone it was 1600  $\mu m$  ( $\pm 310 \mu m$  SD) (Fig. 6). From the distance histogram it was obvious that CTCs appear in approximately the same number in each measurement interval in the inner zone, and in the outer zone the number of CTCs was smaller but again more or less constant. The round cells (RC) appeared very irregular in their distribution, due to the fact that 80% of them were clustered around blood vessels. Polymorphonuclear leukocytes (PNC) have been found only rarely in the soft tissue. Near the implant only few

TABLE II The numbers for all histological structures in the inner zone with the standard error of the mean ( $n/\text{mm}^2 \pm \text{SEM}$ ) summarized according to the clinical symptoms of the patients (SV = small vessels, MV = medium vessels, LV = large vessels, CTC = connective tissue cells, PNC = polymorphonuclear leukocytes, MS = mast cells, MP = macrophages, RC = round cells)

Symptoms	n	SV	MV	LV	CTC	PNC	MS	MP	RC
No pain	25	$7.4 \pm 2.1$	$0.2 \pm 0.07$	$0.01 \pm 0.01$	$810 \pm 29$	$0.03 \pm 0.02$	$6.4 \pm 1.5$	$6.8 \pm 1.8$	$40 \pm 5.7$
Slight pain	20	$9.5 \pm 1.8$	$0.3 \pm 0.1$	$0.04 \pm 0.04$	$895 \pm 38$	$0.1 \pm 0.08$	$6.4 \pm 1.4$	$3.8 \pm 1.3$	$57 \pm 11$
Severe pain	3	$6.6 \pm 4.3$	$0.5 \pm 0.0$	$0.1 \pm 0.1$	$811 \pm 36$	$0.25 \pm 0.25$	$11.8 \pm 0.7$	$15.3 \pm 6.7$	$165 \pm 4.5$
Weather	11	$5.8 \pm 1.5$	$0.4 \pm 0.4$	$0.1 \pm 0.1$	$830 \pm 38$	$0.2 \pm 0.1$	$2.6 \pm 0.9$	$68.0 \pm 60$	$39 \pm 8.3$
Sensitivity									

TABLE III The numbers for all histological structures in the outer zone with the standard error of the mean ( $n/\text{mm}^2 \pm \text{SEM}$ ) summarized according to the clinical symptoms of the patients (for abbreviations see Table II)

Symptoms	n	SV	MV	LV	CTC	PNC	MS	MP	RC
No pain	25	$30.7 \pm 2.5$	$3.5 \pm 0.4$	$0.9 \pm 0.3$	$545 \pm 14$	$0.2 \pm 0.04$	$25.0 \pm 2.5$	$17.8 \pm 2.4$	$75 \pm 12$
Slight pain	20	$43.0 \pm 5.7$	$5.6 \pm 0.6$	$1.7 \pm 0.4$	$613 \pm 27$	$0.4 \pm 0.3$	$29.7 \pm 2.5$	$33.6 \pm 6.1$	$153 \pm 29$
Severe pain	3	$34.7 \pm 3.3$	$5.3 \pm 0.7$	$1.3 \pm 0.3$	$619 \pm 7$	0.0	$26.5 \pm 2.5$	$41.9 \pm 12$	$301 \pm 120$
Weather	11	$28.7 \pm 6.5$	$3.8 \pm 1.5$	$1.5 \pm 0.9$	$597 \pm 42$	$0.5 \pm 0.05$	$17.3 \pm 5.0$	$24.0 \pm 8.2$	$57 \pm 19$
Sensitivity									

small blood vessels were found. With increasing distance from the implant the number and diameter of blood vessels also increased.

An attempt was made to find a correlation between clinical and histological results. In Tables II and III the histological results are summarized and correlated with the clinical symptoms of the patients. In those patients who were complaining of local pain, a significantly higher number of RCs ( $p = 0.001$ ) was found in both zones, whereas macrophages (MP) were only significantly increased in the outer zone. For the blood vessels, and CTCs the difference in population was higher between the two zones than among patients with and without pain. The PNCs were rarely found in either zone. The statistical evaluation of the histological results in correlation to the severity of the fracture did not show significant differences.

In the two tissue samples in which strong discolouration was observed and in the samples with slight discolouration (described macroscopically at retrieval), we found titanium particles in the histological sections. The presence of titanium particles or wear debris was confirmed qualitatively by atomic absorption analyses. There have been no indications of any adverse tissue reactions, e.g. no round cell infiltration was noticed around these titanium particles (Fig. 7). Furthermore, no statistically significant differences in the number of cells or blood vessels could be found between tissue samples with either slight or strong tissue discolouration or without discolouration. We only examined the soft tissue at retrieval of the plates, therefore no evaluation of the histomorphometric parameters was possible over time.

## 5. Discussion

In clinical practice patients describe rather frequent slight local pain symptoms after the treatment of bone fractures, even though this does not disturb them in daily life. The present prospective multicentric clinical

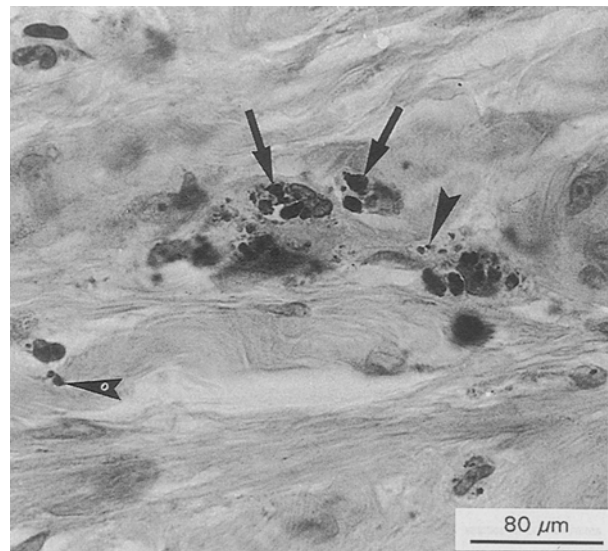


Figure 7 The same sample as seen in Fig. 6, but at a nominal magnification of 400x (Giemsa staining). The black particles represent titanium as detected by atom absorption analyses. They can be found unphagocysed (arrowheads) and phagocysed by macrophages (arrows). Macrophages containing titanium particles show normal form and structure.

study allows to a certain extent a correlation of the symptoms of the patients with the local tissue reaction. It was interesting to see that RCs, and partially MPs are locally significantly higher in patients with local pain compared to patients without pain symptoms.

Blood vessels are found in a high number in granulation tissue which is present in the initial phase of wound healing [30]. The number of blood vessels is directly correlated with the local volume of blood flow and with the oxygen consumption [31]. The outer zone carries more blood vessels, which was particularly true for the small vessels. A correlation with pain does not seem to be evident. The number of

blood vessels in normal human pretibial soft tissue without fracture or internal fixation was found in the same range as for patients of this study without pain [37]. Our results are comparable to these of a similar study, in which stainless steel implants were used [38].

Lymphocytes are round cells derived both from the bone marrow and from lymph nodes. Small numbers of lymphocytes are always present at sites of resolving injury, and large collections are characteristic of immunologic injury [32]. The RCs are significantly higher ( $p = 0.01$ ) in patients complaining of local pain. About 80% of the RCs lie in clusters around blood vessels. The lymphoid cells can be divided into subgroups T-LC or B-LC by an immunological staining method [33]. The samples of 19 patients of this study were analysed in parallel using an immunological staining method [34]. It has been shown that the RC population is composed of T-lymphocytes; no B-lymphocytes were observed. A large number of T-lymphocytes expressed IL2 receptors indicating that there is some continued stimulation that makes the T-lymphocytes active. Together with an increased number of MPs, this is consistent with a chronic granulomatous inflammatory reaction, and a delayed hypersensitivity reaction cannot be excluded [34]. The stimulant for the activation of T-LC is still unclear, further detailed analyses of the tissue are needed. The increased number of RCs and MPs in patients with local pain seems to be part of a chronic inflammatory reaction, which may cause pain.

Since it is known that an immunogen is first handled by a class of antigen-presenting cells (exemplified by the macrophages or closely related cells) that render the immunogen to a form recognizable by the T-lymphocytes [35], we were interested in the number of MPs. The number is an indicator of the quantity of foreign material (wear, corrosion products) or natural deposits of the body (iron from erythrocytes after microbleeding). The MPs are very important in the control of acute inflammation [36]. They arrive more slowly than do neutrophils, but their persistence and phagocytosis promote organization of tissue repair. Only MPs containing phagocysed material could be identified and most of the cells were located around blood vessels. In patients with local pain symptoms a significantly higher number of MPs ( $p = 0.01$ ) was found in the outer zone. In patients without local pain the cellular population in the soft tissue adjacent to the implants resembles that of a repair tissue. In a similar clinical study, in which stainless steel implants were used, a higher number of MPs was found in the adjacent soft tissue. Although a direct comparison of histological data between studies is difficult, a general statement can be made that compared to titanium a greater number of MPs is observed in the soft tissue adjacent to steel implants. A detailed study using LC-DCP implants made from stainless steel is planned to obtain more information concerning these histological differences.

In about half of the patients a localized tissue discolouration was observed, where wear took place at the plate/screw junction, and using atom absorption analyses the presence of titanium was qualitatively

confirmed. The visible debris of titanium, however, did not appear to be the focus of cellular reaction [34]. No significant difference in the number of cells or blood vessels could be found between the tissue samples with and without tissue discolouration at retrieval time.

## 6. Conclusions

Patients with local symptoms of pain after operative fracture treatment were found to have a significantly higher number of round cells and macrophages in the soft tissue covering the plate at retrieval. This is consistent with a chronic granulomatous inflammatory reaction. The localized tissue discolouration observed in about half of the patients was confirmed to be due to titanium, but it was not the focus of cellular reaction and was not correlated with pain. In general the implant showed a good biocompatibility with excellent or good clinical results in 96% of patients.

## Acknowledgements

The authors would like to express their gratitude to Professor S.M. Perren for his helpful collaboration, Mrs E. Rampoldi for histological work and Dr J. Cordey for assisting the statistical calculations. Mr U. Schlegel and professor B. Rahn are marked for their support with computer programming and developing the evaluation system. Their advice is gratefully acknowledged.

This work was supported by the AO/ASIF foundation.

## References

1. T. P. RUEDI, *Heftc Unfallheilkunde* **123** (1975) 1.
2. P. G. LAING, National Bureau of Standards, Special Publication (Washington DC, 1977) p. 31.
3. B. A. RAHN, V. GERET, C. CAPAUL, M. LARDI and B. SOLOTHURNMANN in "Morphometric evaluation of tissue reaction to implants using low cost digitizing techniques", edited by A.J.C. Lee, T. Albrektsson and P.J. Branemark (John Wiley and Sons Ltd, Chichester, 1982) p. 263.
4. T. N. SALTHOUSE and B. F. MATLAGA, in "Biomaterials in reconstructive surgery", edited by L. R. Rubin (Mosby, St Louis, 1983) p. 40.
5. T. ALBREKTSSON, *CRB Crit. Rev. Biocomp.* **1** (1985) 53.
6. S. M. PERREN and O. POHLER, *AO/ASIF Dialogue* **1** (1987) 11.
7. R. L. WILLIAMS and D. F. WILLIAMS, *J. Biomed. Mater. Res.* **23** (1989) 339.
8. S. M. PERREN, K. KLAUE, O. POHLER, M. PREDIERI, S. STEINEMANN and E. GAUTIER, *Arch. Orthop. Trauma Surg.* **109** (1990) 304.
9. L. LINDER and J. LUNDSKOG, *Injury* **6** (1975) 277.
10. J. P. SIMPSON, in "Biological and biomechanical performance of biomaterials", edited by P. Christel, A. Meunier, and A.J.S. Lee (Elsevier, Amsterdam, 1986) p. 63.
11. J. DISEGI and H. WYSS, *Orthopedics* **12** (1989) 75.
12. P. I. BRANEMARK, U. BREINE, J. LINDSTROM, R. ADELL, B. O. HASSON and A. OHLSSON, *Scand. J. Plast. Reconstr. Surg.* **3** (1969) 81.
13. U. N. RIEDE, T. RUEDI and F. LIMACHER, *Arch. Orthop. Unfall, Chir.* **79** (1974) 205.
14. S. G. STEINEMANN and P. A. MAEUSLI, in Proceedings of Sixth World Conference on Titanium, Cannes, June 1988, p. 535.
15. G. L. DE LANGE and K. DONATH, *Biomaterials* **10** (1989) 121.

17. M. S. PETERS, A. L. SCHROETER, H. M. VAN HALE and J. C. BROADBENT, *Contact Dermatitis* **11** (1984) 214.
18. T. ALBREKTSSON, P. L. BRANEMARK, H. A. HANSSON, B. KASEMO, K. LARSSON, I. LUNDSTROEM, D. H. MCQUEEN and R. SKALAK, *Ann. Biomed. Engng* **11** (1983) 1.
19. M. SCHMIDT, *Osteologie* **1** (1992) 222.
20. J. E. SUNDGREN, P. BODOE and I. LUNDSTROEM, *J. Colloid. Interface Sci.* **110** (1986) 9.
21. J. LAUSMAA, Theses for Physics University of Göteborg (1991) p. 360.
22. B. A. RAHN, H. W. GERBER, J. SIMPSON, F. STRAUMANN and S. M. PERREN, *Biomaterials* (1980) 39.
23. E. J. ANDREWS, P. W. TODD and N. E. KUKULINSKI, *J. Biomed. Mater. Res.* **13** (1979) 173.
24. K. J. BUNDY, O. C. ROBERTS, K. O'CONNOR, B. RAHN and V. McLOED, in Proceedings of 10th European Conference on Biomaterials, Davos, September 1993, p. 14.
25. A. UNGERSBOECK and B. RAHN, *J. Mater. Sci. Mater. Med.* **5** (1994) 434.
26. A. UNGERSBOECK, U. SCHLEGEL and B. RAHN, *ibid.* **5** (1994) 557.
27. M. E. MUELLER, M. ALLGOEWER, R. SCHNEIDER and H. WILLENEGGER, in "Manual of internal fixation", 3rd Edn (Springer Verlag, Heidelberg, 1991) p. 74.
28. M. E. MUELLER, S. NAZARIAN and P. KOCH, in "Classification AO of fractures" (Springer Verlag, Heidelberg, 1987) p. 158.
29. O. BUCHER, in "Cytologie histologie und mikroskopische anatomie des menschen" (Verlag Hans Huber Bern, Zehnte Auflage, 1980) p. 100.
30. S. C. WOODWARD and T. N. SALTHOUSE, in "Handbook of biomaterials evaluation-scientific, technical and clinical testing of implant materials" (Von Recum AF, Macmillian New York, 1986) p. 364.
31. W. F. GANONG, in "Review of medical physiology", 8th Edn (Lange Medical Publications, Los Altos, USA, 1977) p. 646.
32. S. L. ROBBINS and R. S. COTRAN, in "Pathologic basis of disease", 2nd edn (Saunders, Philadelphia, 1979) p. 56.
33. D. G. VINCE, J. A. HUNT and D. F. WILLIAMS, *Biomaterials* **12** (1991) 731.
34. J. A. HUNT, A. UNGERSBOECK and D. F. WILLIAMS, *J. Mater. Sci. Mater. Med.* **5** (1994) 381.
35. C. A. DINARELLO, *Rev. Infect. Dis.* **6** (1984) 51.
36. B. VERNON ROBERTS, in "The macrophage" (Cambridge University Press, Cambridge, 1972) p. 120.
37. Unpublished observations of the author.
38. S. HIERHOLZER and G. HIERHOLZER, "Internal fixation and metal allergy" (Georg Thieme Verlag, New York, 1992) p. 33.

*Received 2 December 1993  
and accepted 20 August 1994*